

12-20-1987

Fetuses of African Elephants (*Loxodonta africana*) in Photographs

Martin S. Fischer

Institut für Biologie III, Lehrstuhl Spezielle Zoologie, Universität Tübingen Auf der Morgenstelle

Uschi Trautmann

Institut für Biologie III, Lehrstuhl Spezielle Zoologie, Universität Tübingen Auf der Morgenstelle

Follow this and additional works at: <https://digitalcommons.wayne.edu/elephant>

Recommended Citation

Fischer, M. S., & Trautmann, U. (1987). Fetuses of African Elephants (*Loxodonta africana*) in Photographs. *Elephant*, 2(3), 40-45.
Doi: 10.22237/elephant/1521732098

This Article is brought to you for free and open access by the Open Access Journals at DigitalCommons@WayneState. It has been accepted for inclusion in *Elephant* by an authorized editor of DigitalCommons@WayneState.

Fetuses of African Elephants (*Loxodonta africana*) in Photographs

Cover Page Footnote

We are greatly indebted to J. S. Perry, R. M. Laws, P. Langer, W. P. Lockett, and W. Maier for providing us with the fetuses depicted in this paper.

FETUSES OF AFRICAN ELEPHANTS (Loxodonta africana) IN PHOTOGRAPHS

by Martin S. Fischer and Uschi Trautmann

Institut für Biologie III, Lehrstuhl Spezielle Zoologie,
Universität Tübingen Auf der Morgenstelle 28, D-7400 Tübingen,
FEDERAL REPUBLIC OF GERMANY

ABSTRACT: Noticing that almost nothing has been published on the early ontogenetic development of elephants, we want to start to fill this gap by presenting pictures of elephant fetuses. All fetuses are African elephants (Loxodonta africana). Unfortunately, we do not know the age of the fetuses except for the largest one which is about 8 months old. All specimens are fixated in 4% formalin. The legends will point to the peculiarities in the external morphology of each fetus.

Obtaining elephant fetuses for research is not an everyday event. Thus we, foremost, thank those individuals who helped us in obtaining the fetuses described here (see under acknowledgments). We take this opportunity to ask our readers to please help us procure additional specimens, with all pertinent information, for much embryological work needs to be conducted to elucidate elephant anatomy, especially head and limb development.

Most of the research on elephant fetuses published are on specimens larger than ours (e.g., Amoroso and Perry, 1964; Perry, 1974). Toldt (1913) gives a list of 10 fetuses and references on fetal elephants known up to this date and gives a description of external morphology of an Asian elephant, Elephas maximus. Bolk (1917) has published an account on the external morphology of an African elephant and a few macroscopic observations on the skull of the fetus, which is a little bit bigger (total length, i. e. tip of trunk to tip of tail, 500 mm) than our specimen No. 4. Wettstein (1920) compares three fetuses of African elephants between 233 mm and 342 mm crown-rump length (CRL) to the description of the Asian elephant of Toldt. The specimen of which Eales (1926, 1928, 1929) made her excellent work on the anatomy of a fetal African elephant measured 225 mm CRL. Hill (1938a) added to the external and radiological anatomy of a 315 mm fetus (CRL) of an Asian elephant, and in the same volume (Hill, 1938b) to the cardiac anatomy of the same specimen. We find several studies dealing with the tooth development in fetal elephants (Bolk 1917, Adloff 1919, Anthony 1933, Driak 1935), but unfortunately none of them has definitively solved the problem of the homology of the tusk. Of course, this is not a complete bibliography of the literature on elephant fetuses.

Below are photographs and pertinent comments.




Figure 1. The measurements of this elephant fetus are: from tip of trunk to tip of tail (TTL) = 76 mm, crown-rump length (CRL) = 31.5 mm, headlength (HL) = 14.5 mm.

The head is very narrow; it seems to be more or less compressed laterally. We do not know if this is due to a post-mortem event. As to the future trunk there seems to be a paradoxical situation. In this youngest specimen we cannot find a separate upper lip, whereas the next older (Fig. 2) shows a clear distinction between upper lip and proboscis. To explain this phenomenon we will have to study histological sections through the head.

We are facing a comparable problem with the fore and hind limbs. At first glance specimen No. 1 seems to have more differentiated feet than specimen No. 2. The latter shows the beginning of the pillar-like extremity typical for elephants, whereas specimen No. 1 has a clear mesaxonic arrangement with the third digits elongated. We think that perhaps specimen No. 1 reflects the phylogenetically older stage. Distinct elephantine characters of specimen No. 1 are: the elongated snout, the shape of the ears, the vertically orientated pelvis, the high number of ribs, the "fusion" of the inner side of the thigh and of the upper arm with the abdomen.

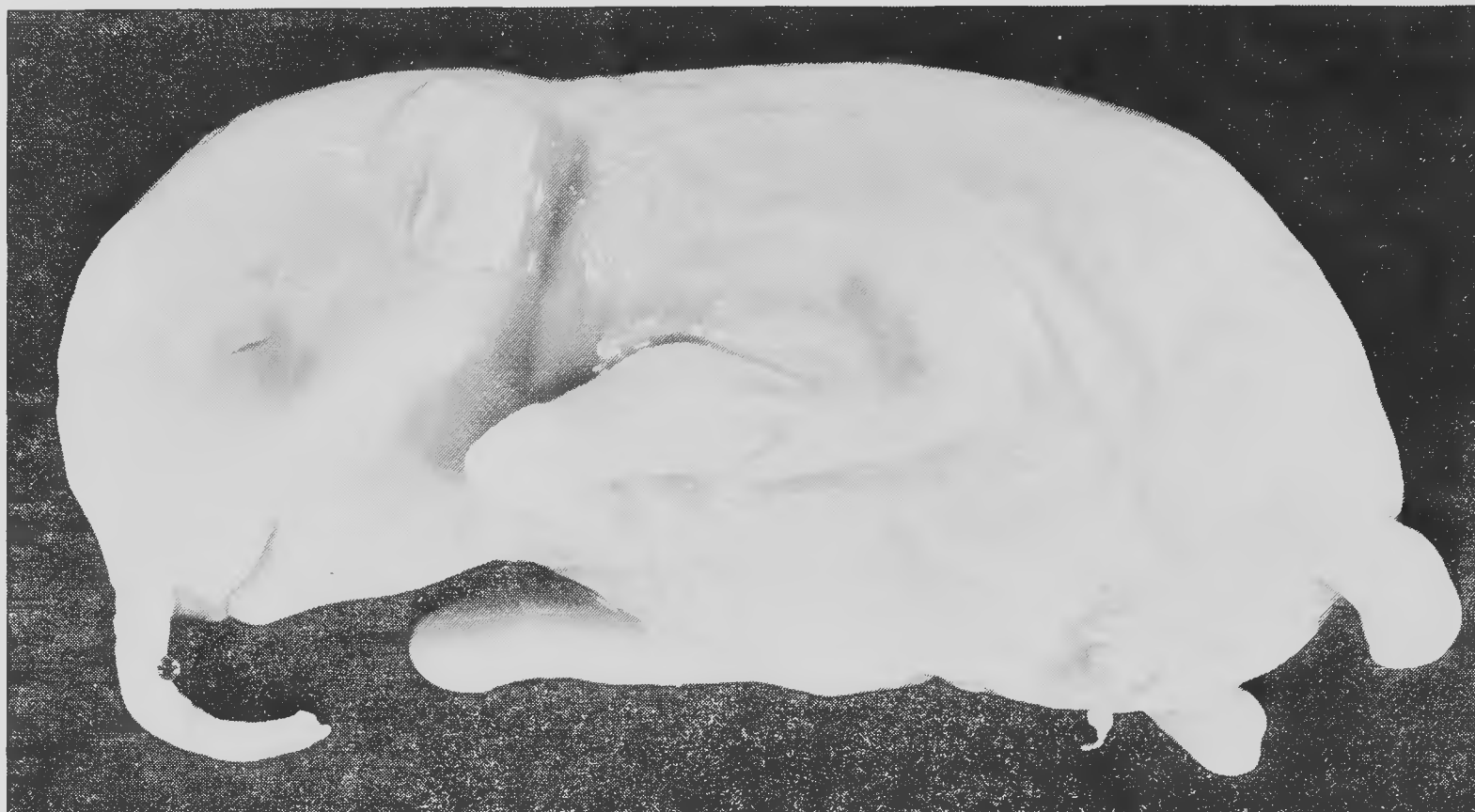

Figure 2. This fetus already displays most elephantine features. Its measurements are: TTL = 310 mm, CRL = 60 mm, Hl = 33 mm, and length of trunk (TL) = 18 mm.

Note that the upper lip is completely distinct from the trunk (Fischer, 1987). This observation contradicts all earlier statements (e.g., Toldt 1913, Bolk 1917, Friant 1933) that the upper lip is always fused to the ventral side of the trunk. The limbs show no sign of digits. In comparison to the other fetuses the tail is unusually short.



Figure 3. An x-ray photograph of the same fetus shown in Fig. 2. Note that ossification has progressed, especially in the carpus and tarsus.

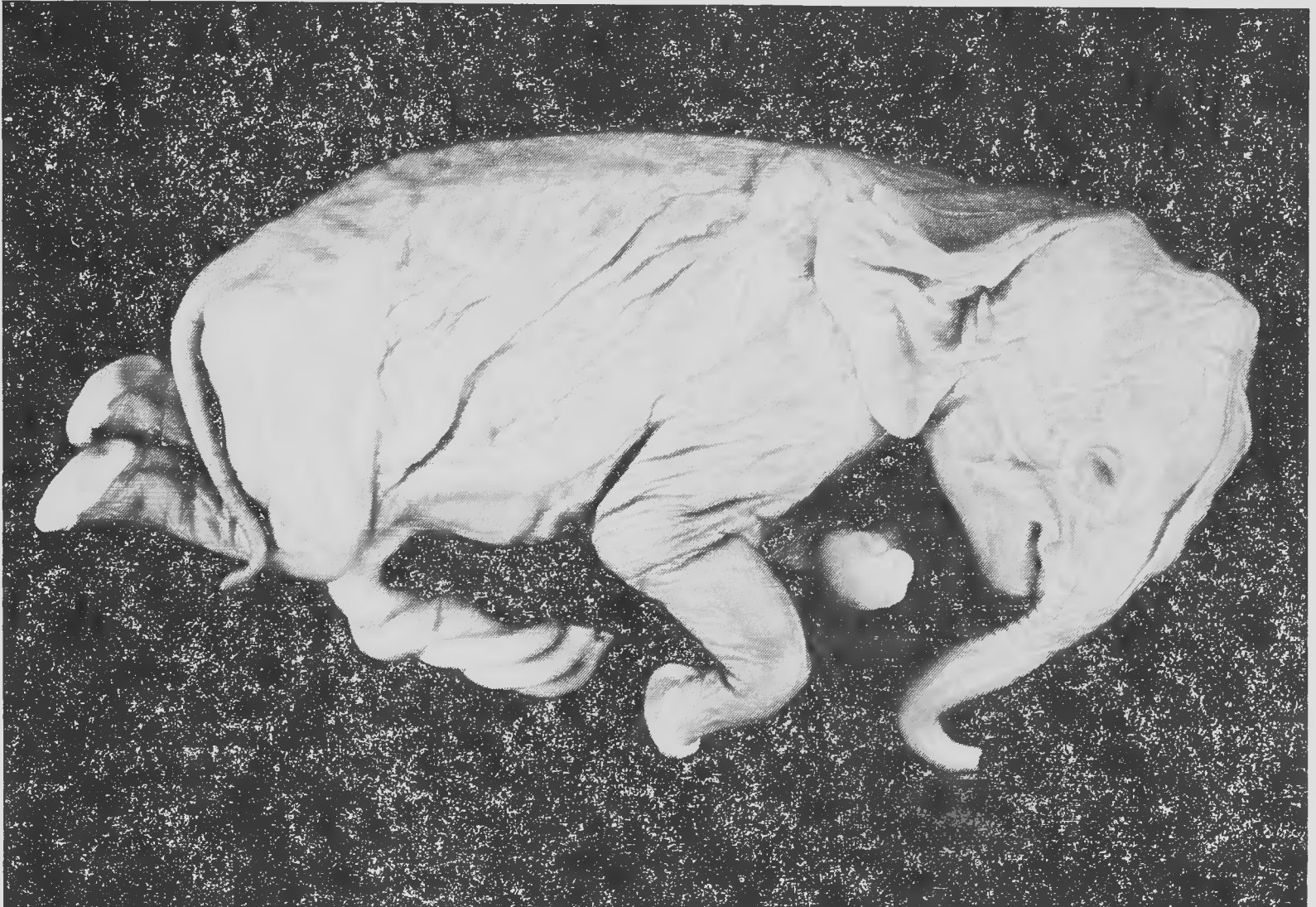

Figure 4. The measurements of specimen No. 3 are: TTL = 310 mm, CRL = 147 mm, HL = 58 mm, and TL = 50 mm.

There is nothing unusual about the external morphology of this elephant, at least nothing which seems to be specific for a fetus, except perhaps the strong umbilical cord. As with the previous specimens, it is difficult even to guess the age. It would be important to get data on the age of these fetuses.

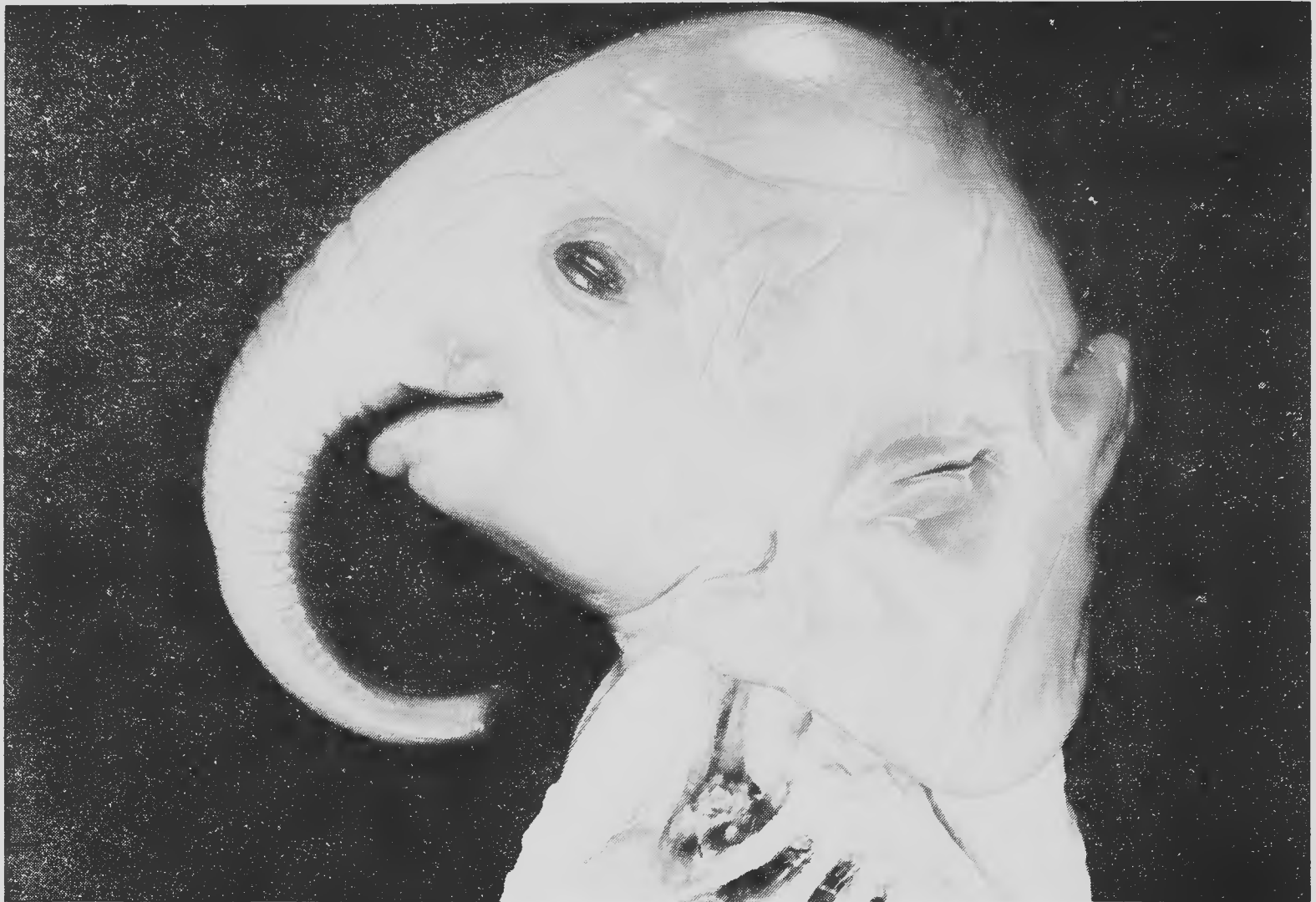

Figure 5. Specimen No. 4 measures: TTL = 440 mm, CRL = 220 mm, HL = 79 mm, TL = 77 mm. This specimen is approximately the size of the fetus of which the external morphology has been extensively described by Bolk (1917).

We realize that the typical shape of an elephant's head with a high forehead and skull roof is seen in all four fetuses and obviously is achieved very early in ontogeny. The age of this fetus has been estimated by the rangers of the Kruger National Park (Republic of South Africa) to be around eight months. This estimate seems to be reasonable, because Toldt's (1913) 565 mm fetus has been given an age of 11 months according to the known date of conception of the dam. A description of the digestive tract of this fetus has been published by Langer (1982, 1984). Much more embryological work remains to be conducted, especially when working with a mammal whose gestation period can be about 22 months long.

ACKNOWLEDGEMENTS

We are greatly indebted to J. S. Perry, R. M. Laws, P. Langer, W. P. Lockett, and W. Maier for providing us with the fetuses depicted in this paper.

LITERATURE CITED

- Adloff, P. 1919. Zur Ontogenie des Elefantengebisses. *Anat. Anz.*, 52:534-540.
- Amoroso, E. C., and J. S. Perry. 1964. The foetal membranes and placenta of the African elephant, (*Loxodonta africana*). *Phil. Trans. Roy. Soc.* London, (B), 248:1-34.
- Anthony, R. 1933. Recherches sur les incisives superieures des Elephantidae actuels et fossiles (Elephants et Mastodontes). *Arch. Mus. Hist. Nat.*, 10:61-124.
- Bolk, L. 1917. Anatomische Bemerkungen ueber einen Fetus von *Elephas africanus*. *Verh. Koninkl. Akad. Wet. Amsterdam*, 2, sect., 19 (6):1-40.
- Driak, F. 1935. Studien der Zahnanlagen an einem Foetus von *Elephas indicus*. *Morph. Jb.*, 75:1-14.
- Eales, N. 1926. The anatomy of the head of a foetal African elephant, *Elephas africanus* (*Loxodonta africana*). *Trans. Roy. Soc. Edin.*, 54, part III (No. 11):491-551.
- Eales, N. 1928. The anatomy of a foetal African elephant, *Elephas africanus* (*Loxodonta africana*). Part II. The body muscles. *Trans. Roy. Soc. Edin.*, 55, part III (No. 25):609-642.
- Eales, N. 1929. The anatomy of a foetal African elephant, *Elephas africanus* (*Loxodonta africana*). Part III. The contents of the thorax and abdomen, and the skeleton. *Trans. Roy. Soc. Edin.*, 56, Part I (No. 11):203-246.
- Fischer, M. S. 1987. Die Oberlippe des Elefanten. *Z. Saeugetierk*, 52:262-263.
- Friant, M. 1933. La regression de la levre superieure au cours de l'ontogenie individuelle chez l'elephant. *C. R. Acad. Sci. Paris*, (seance du 20 mars 1933):878-879.
- Hill, W. C. O. 1938a. The external and radiological anatomy of a foetal Asiatic elephant. *Ceylon J. Sci. (B)*, 21:31-43.
- Hill, W. C. O. 1938b. Studies on the cardiac anatomy of the elephant II. The heart and great vessels of the foetal Asiatic elephant. *Ceylon J. Sci. (B)*, 21:45-61.
- Langer, P. 1982. Wandel der Querschnittsgeometrie des Darmtraktes als Anpassung an die Herbivorie bei Saeugetieren. (Abstract). *Verh. Dtsch. Zool. Ges.*, 75:280.
- Langer, P. 1984. Anatomical and nutritional adaptations in wild herbivores. Pp. 185-203, in *Herbivore nutrition in the subtropics and tropics* (F. M. C. Gilchrist and R. I. Mackie, eds.). Science Press, Craighall, South Africa.
- Perry, J. S. 1974. Implantation, foetal membranes and early placentation of the African elephant, *Loxodonta africana*. *Phil. Trans. Roy. Soc. (B)*, 269 (897):109-135.
- Toldt, K. jun. 1913. Ueber die aeuszere Koerpergestalt eines Fetus von *Elephas maximus* (= *indicus*) L., nebst vergleichenden Betrachtungen ueber sein Integument, insbesondere ueber die Behaarung. *Denkschr. Kaiserl. Akad. Wiss. Wien, Mathem. Naturwiss. Cl.*, 15:259-300.
- Wettstein, O. 1920. Aeuszere morphologische Unterschiede zwischen Feten von *Elephas africanus* and *E. maximus*. *Arkiv Zool.*, 13 (15):1-15.